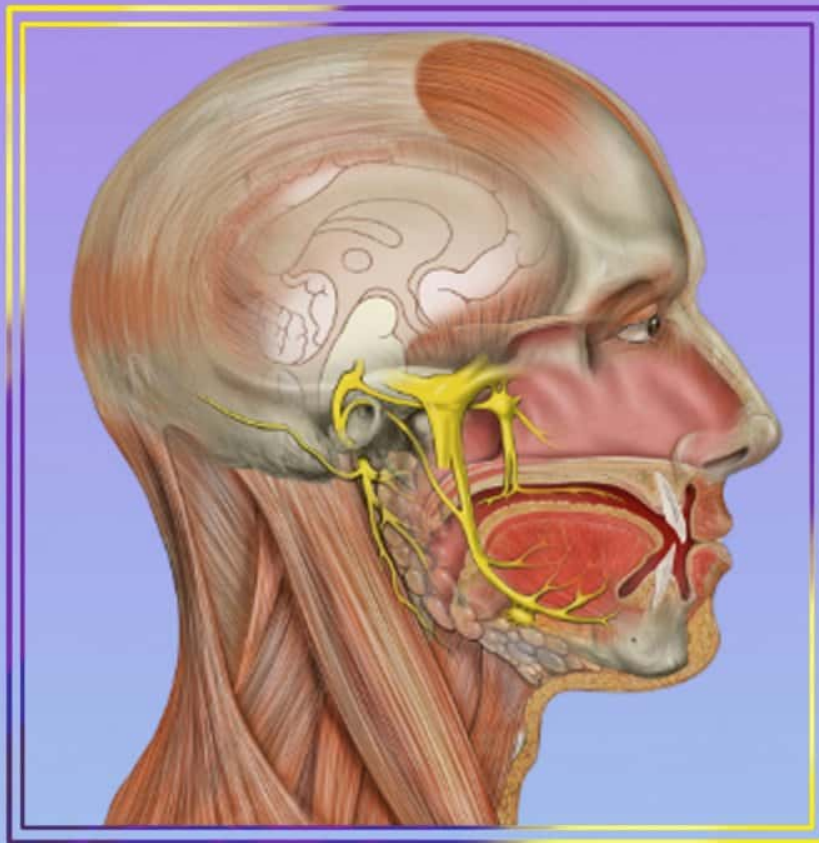


VISUAL MNEMONICS ANATOMY



100+
Slides



MEDINAZ

Dr. Nazmul Alam



Copyright © 2018 by Nazmul Alam. All rights reserved. No part of this publication may be reproduced or distributed in any form or by any means, or stored in a database or retrieval system, without the prior written permission of the publisher.

TERMS OF USE

This is a copyrighted work and Medinaz and its licensors reserve all rights in and to the work. Use of this work is subject to these terms. Except as permitted under the Copyright Act of 1976 and the right to store and retrieve one copy of the work, you may not decompile, disassemble, reverse engineer, reproduce, modify, create derivative works based upon, transmit, distribute, disseminate, sell, publish or sublicense the work or any part of it without Medinaz's prior consent. You may use the work for your own noncommercial and personal use; any other use of the work is strictly prohibited. Your right to use the work may be terminated if you fail to comply with these terms.



CONTENTS

- **NEUROANATOMY**
- **EMBRYOLOGY**
- **HISTOLOGY**
- **GROSS ANATOMY ABDOMEN**
- **GROSS ANATOMY HEAD & NECK**
- **GROSS ANATOMY UPPER LIMB**
- **GROSS ANATOMY LOWER LIMB**
- **GROSS ANATOMY THORAX**
- **GROSS ANATOMY PELVIS**
- **MISCELLANEOUS**



NEUROANATOMY

@NEETPGSURGEON

Deep Cerebellar Nuclei

www.medinaz.com

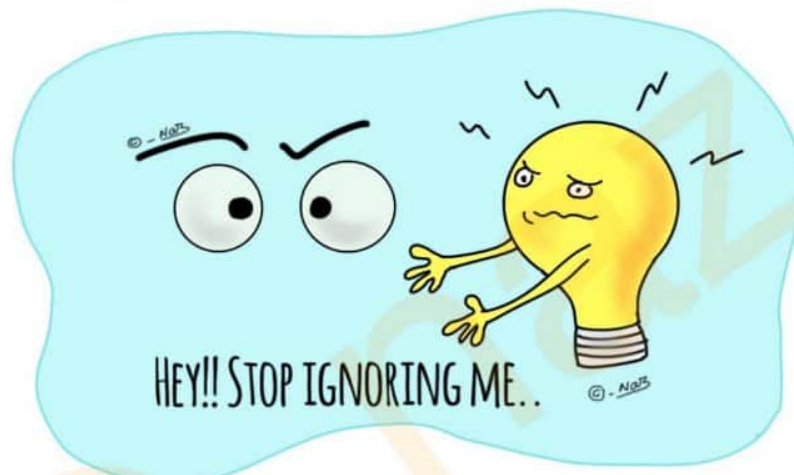
From medial to lateral:

Fastigial
Globose
Emboliform
Dentate

“Fat Girls Eat Donuts”



Argyll Robertson Pupil



Argyll Robertson Pupil (ARP)

→ Accommodation Reflex Present (ARP)
ARP
← Pupillary Reflex Absent (PRA)

Auditory Pathway

www.medinaz.com

“Hungry Girls 8 (ate)

Nothing To SLIM Themselves”

Hair cells
spiral Ganglion
cranial nerve 8
Nuclei (cochlear)
Trapezoid body
Superior olivary nucleus
Lateral lemniscus
Inferior colliculus
Medial geniculate body
Transverse temporal gyrus

© - Med5



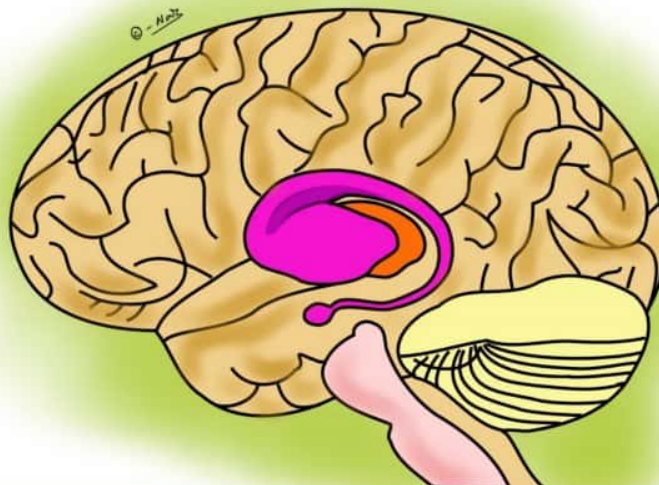
Basal Ganglia Pathway

www.medinaz.com

Indirect pathway = Inhibitory

Direct pathway hence Excitatory

© - Med5



CRANIAL NERVES

O ne	O lfactory
O f	O ptic
O ur	O culomotor
T elugu	T rochlear
T eacher	T rigeminal
A sked	A bducens
F or	F acial
V ery	V estibulococlear
G ood	G lossopharyngeal
V ada	V agus
A nd	A ccessory
H alwa	H ypoglossal




Cranial nerve Types

Cranial nerve

(S) ome	1
(S) ays	2
(M) oney	3
(M) atters	4
(B) ut	5
(M) y	6
(B) rother	7
(S) ays	8
(B) ig	9
(B) ooks	10
(M) atter	11
(M) ost	12

S = Sensory
M = Motor
B = Both





The cranial nerves

Oh = Olfactory

Oh = Optic

Oh = Oculomotor

To = Trochlear

Touch = Trigeminal

And = Abducens

Feel = Facial

Very = Vestibulocochlear

Giant = Glossopharyngeal

Volcano = Vagus

Ahh = Accessory

Hot = Hypoglossal

Cerebellar Damage Signs

www.medinaz.com

Dysdiadochokinesis

Ataxia


Nystagmus

Intention tremor

Slurred speech

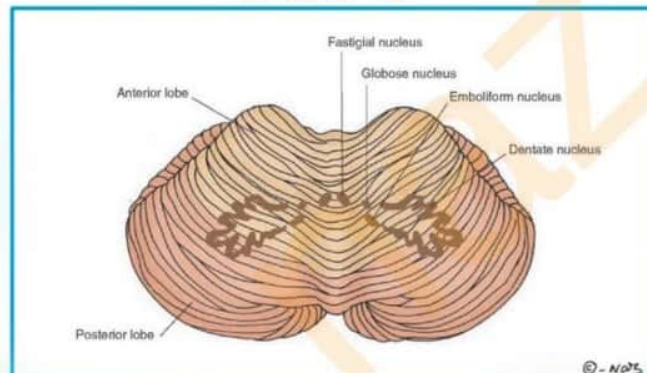
Hypotonia

“**DANISH**”



Cerebellar Nuclei

“**D-E-F-G**”



Dentate nucleus

Emboliform nucleus

Fastigial nucleus

Globose nucleus

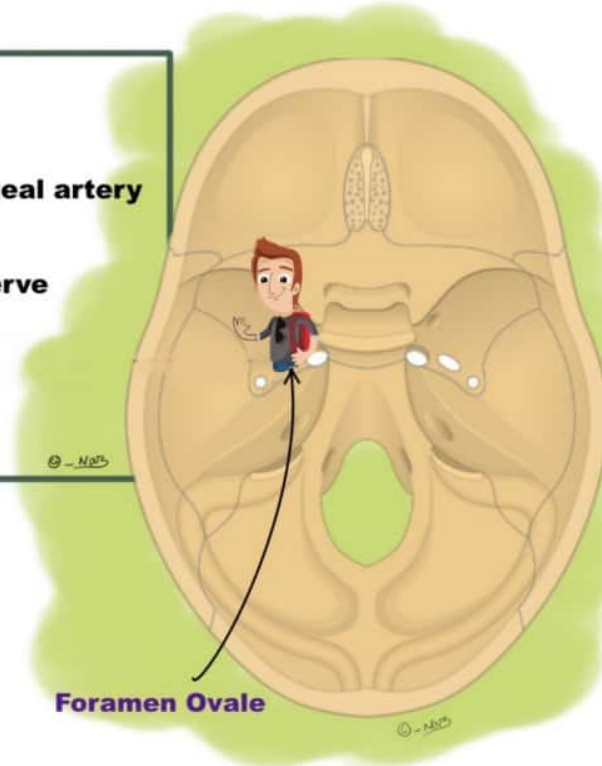
Foramen Ovale contents

Mandibular nerve

Accessory meningeal artery

Lesser petrosal nerve

Emissary vein



Extraocular Muscles Nerve Supply

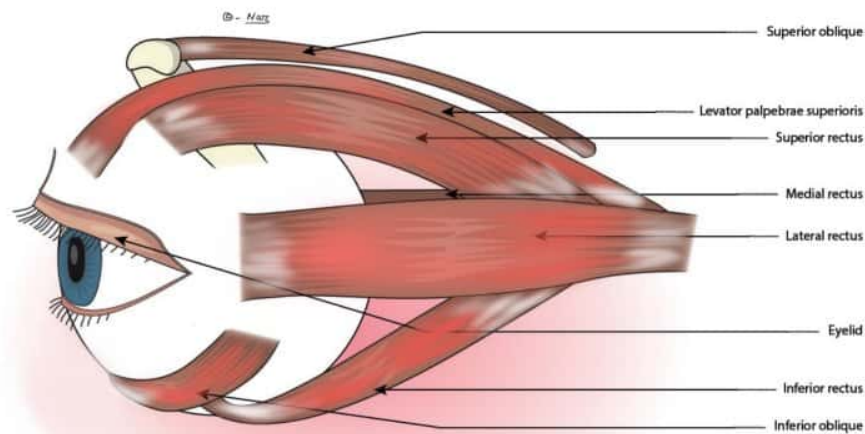
www.medinaz.com

Lateral **R**ectus = 6th cn nerve

Superior **O**blique = 4th cn nerve

Others = 3rd cn nerve

“LR6,SO4,03”



Trigeminal Nerve Branches

www.medinaz.com

“O My Mamma”


Ophthalmic nerve
Maxillary nerve
Mandibular nerve



Maxillary Nerve Branches

Men Gangs are Maximum
In Southern Zone

Middle Meningeal
Gangliar branch to sphenopalatine
ganglion, Greater & lesser palatine
Maxillary
Infraorbital
Superior alveolar
(posterior, middle & anterior)
Zygomatic





Glossopharyngeal Nerve Branches

www.medinaz.com

Muscular
Pharyngeal
Tonsillar
Lingual
Tympanic

“Many People Try
Lawn Tennis”



Ophthalmic Nerve Main Branches

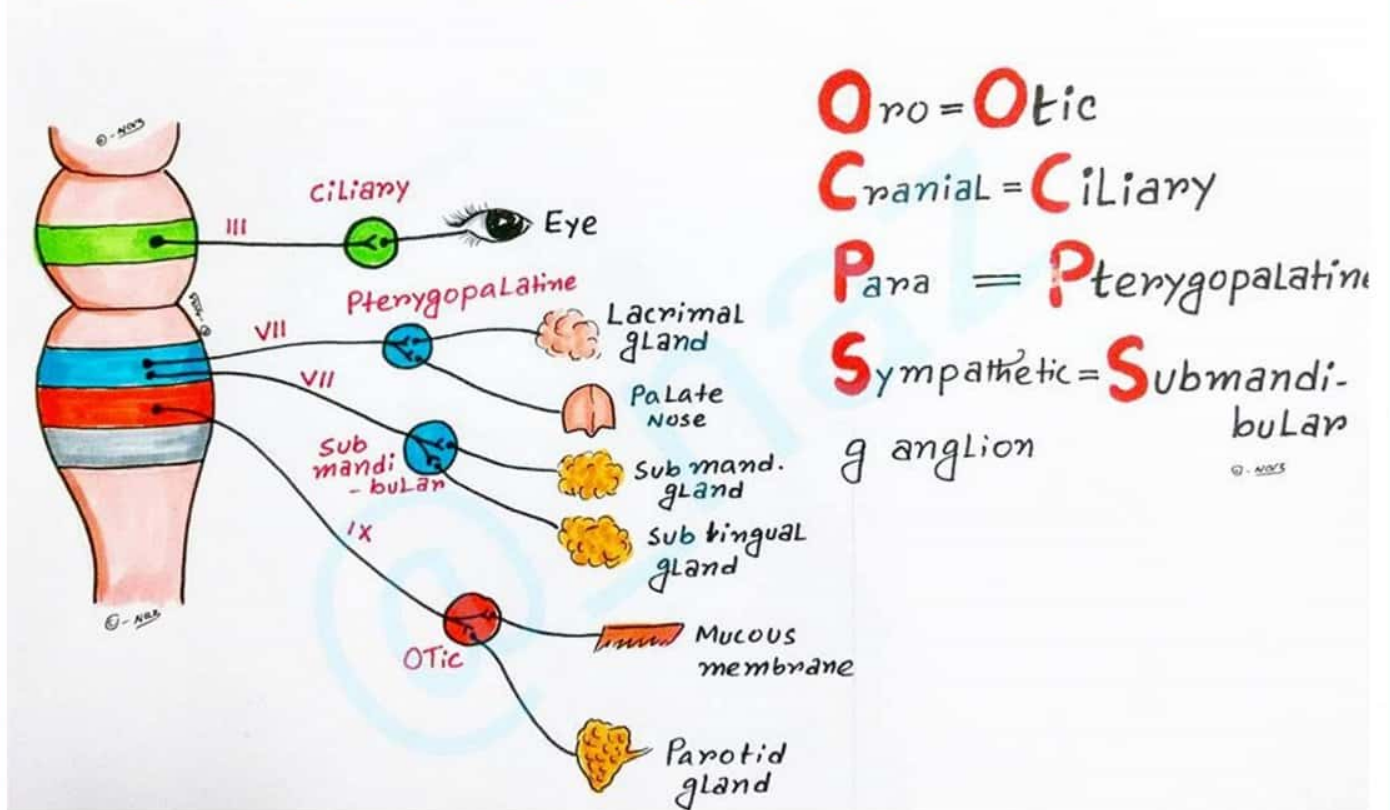
www.medinaz.com

Tentorial
Lacrimal
Frontal
Supratrochlear
Nasociliary
Communicating br.

“To Look For Some
New Candidates”



Parasympathetic ganglion of Head and Neck



Chorea Common Causes

www.medinaz.com

Vascular

Increased RBC (polycythemia)

Toxins - CO, Mg, Hg

Uremia

SLE

Senile chorea

Drugs

APLA syndrome

Neurodegenerative condition -

HD, neuroacanthocytosis, DRPLA

Conception related - pregnancy

Endocrine -

hyperthyroidism, hyperglycaemia

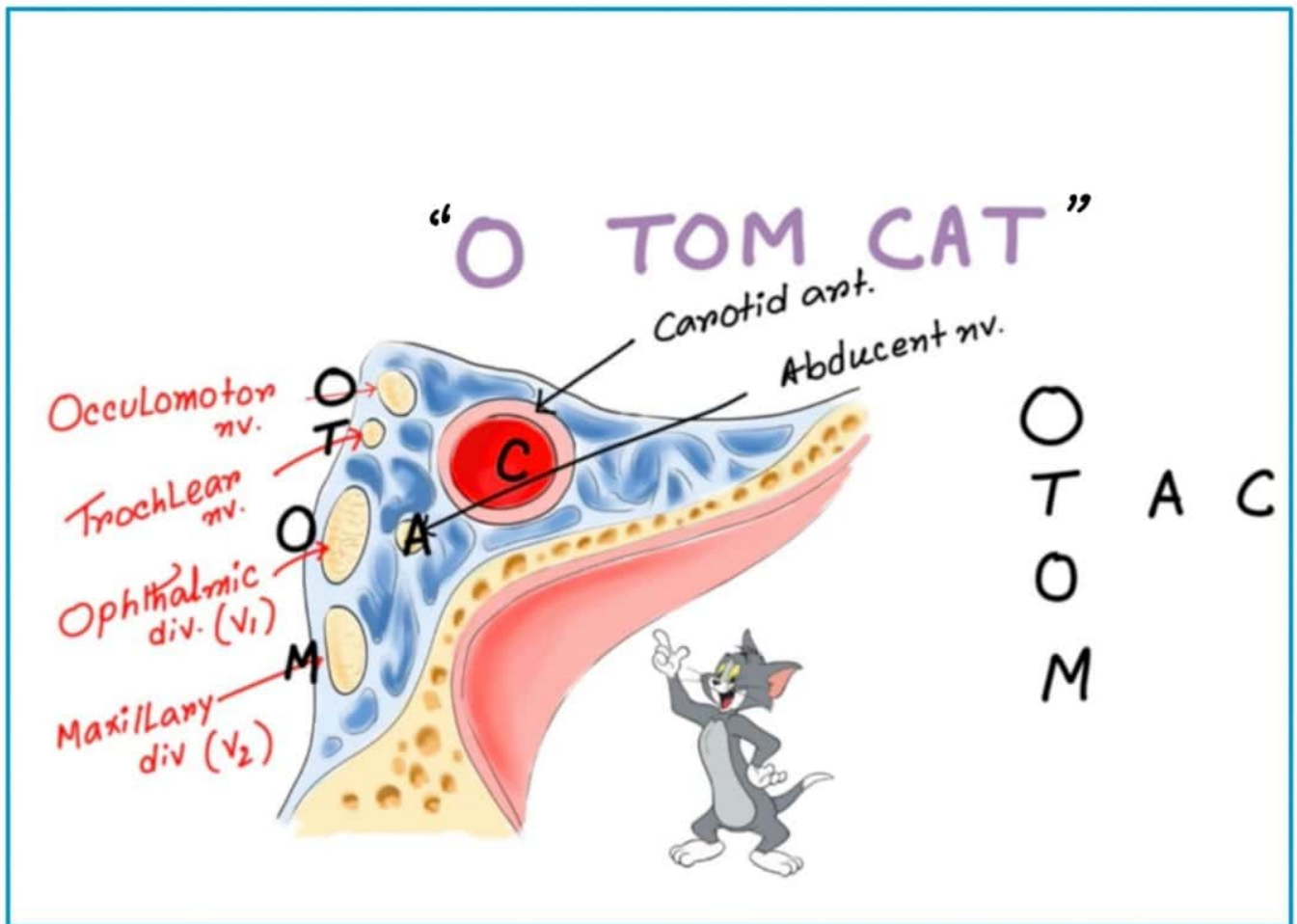
© - N.OTS

“St. VITUS’S DANCE”



Cavernous Sinus Contents

www.medinaz.com





EMBRYOLOGY

@NEETPGSURGEON

Cartilage derivatives of 1st Pharyngeal arch



I' = **I**ncus

M = **M**alleus

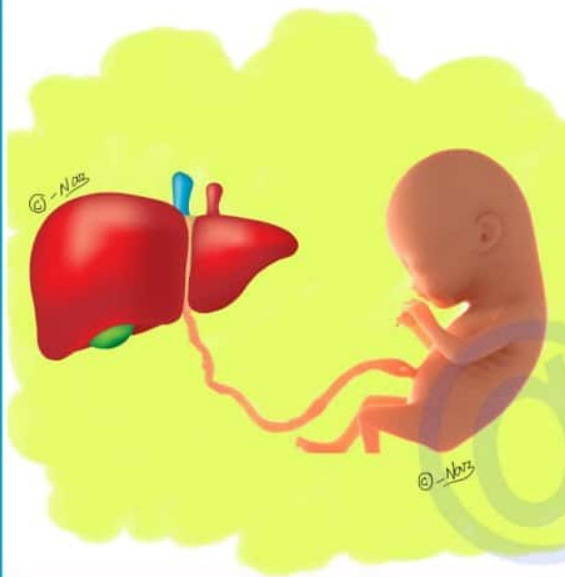
A = **A**nt. Ligament of malleus

Super = **S**pine of Sphenoid

Sexy = **S**phenomandibular Ligament

GirL = **G**enial tubercle of mandible

FATAL ERYTHROPOIESIS



Young → **Yolk sac**

Liver → **Liver**

Synthesizes → **Spleen**

Blood → **Bone marrow**

© -Naz

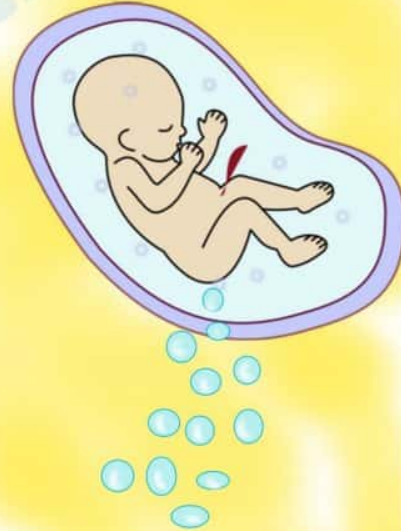

Foregut Derivatives

www.medinaz.com

Lungs
Esophagus
Pancreas
Duodenum (proximal)
Liver
Stomach
Pancreas
Gall bladder

“Little Embryo People Do Like
Swallowing, Producing Gas”



Tooth Eruption



M ama = 1st	M olar = 6 - 7 Years
I s = 1st	I ncisor = 7 - 8 "
I n = 2nd	I ncisor = 8 - 9 "
P ower = 1st	P remolar = 9 - 10 "
P apa = 2nd	P remolar = 10 - 11 "
C an't =	C anine = 11 - 12 "
M ake = 2nd	M olar = 12 - 13 "
M istake = 3rd	M olar = 18 - 25 "

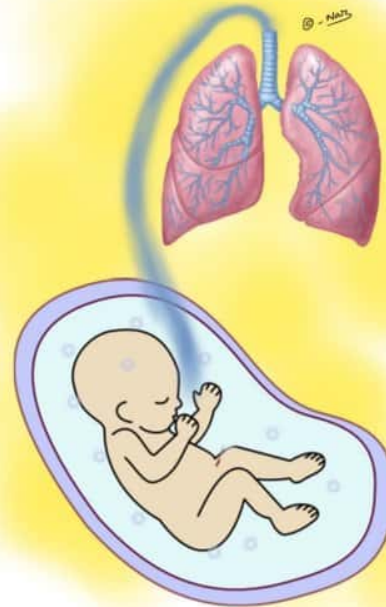

Lung Development Phases

www.medinaz.com

“Every **P**remature **C**hild
Takes **A**ir”

Embryonic period
Pseudo glandular period
Canalicular period
Terminal sac period
Alveolar period

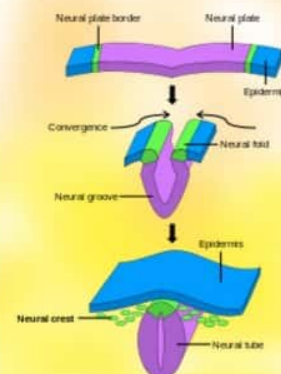


Neural Crest Derivatives

www.medinaz.com

“**P**yaara **SANAM**”

Pia mater
Schwann cells
Arachnoid mater
Neurone (dorsal root ganglion,
sensory ganglion of 5,7,8,9,10,
sympathetic ganglion)
Adrenal medulla (Chromaffin tissue)
Melanocytes



www.medinaz.com



Ocular Structures Derived From Neuroectoderm

www.medinaz.com

Muscles of iris

Optic nerve

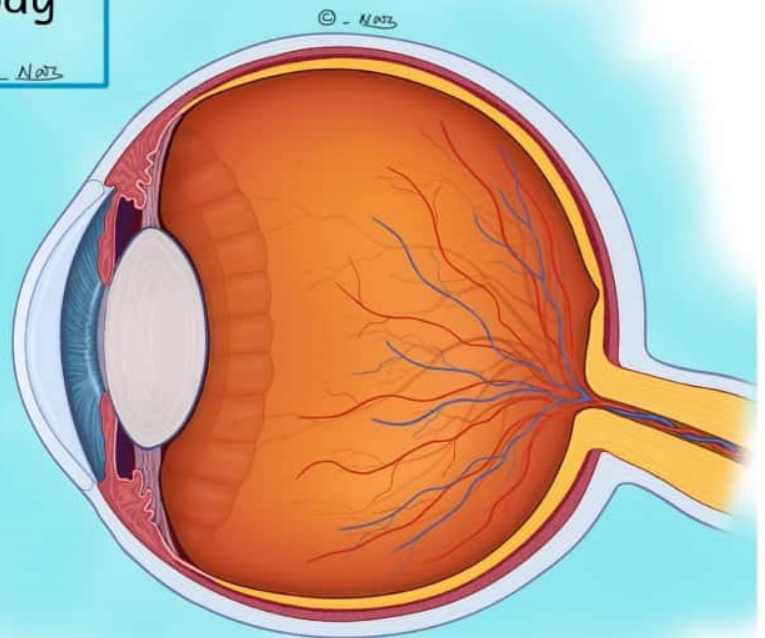
Retina (with RPE)

Epithelium of Iris

Epithelium of Cilliary Body

© - Medz

“MORE”

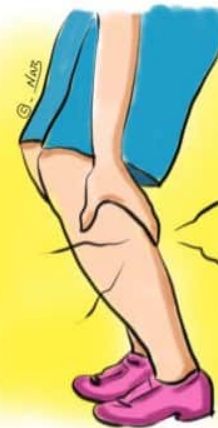

PATAU Syndrome

www.medinaz.com

Cleft lip / palate
Renal abnormalities
cArdiac defects
Microcephaly
Mental retardation
Polydactyly

“CRAMP”



13 letters = Trisomy 13

PATAU Syndrome

Microcephaly

www.medinaz.com

Mental retardation

cleft lip / palate

malformed ears

Cardiac defects

Renal problems

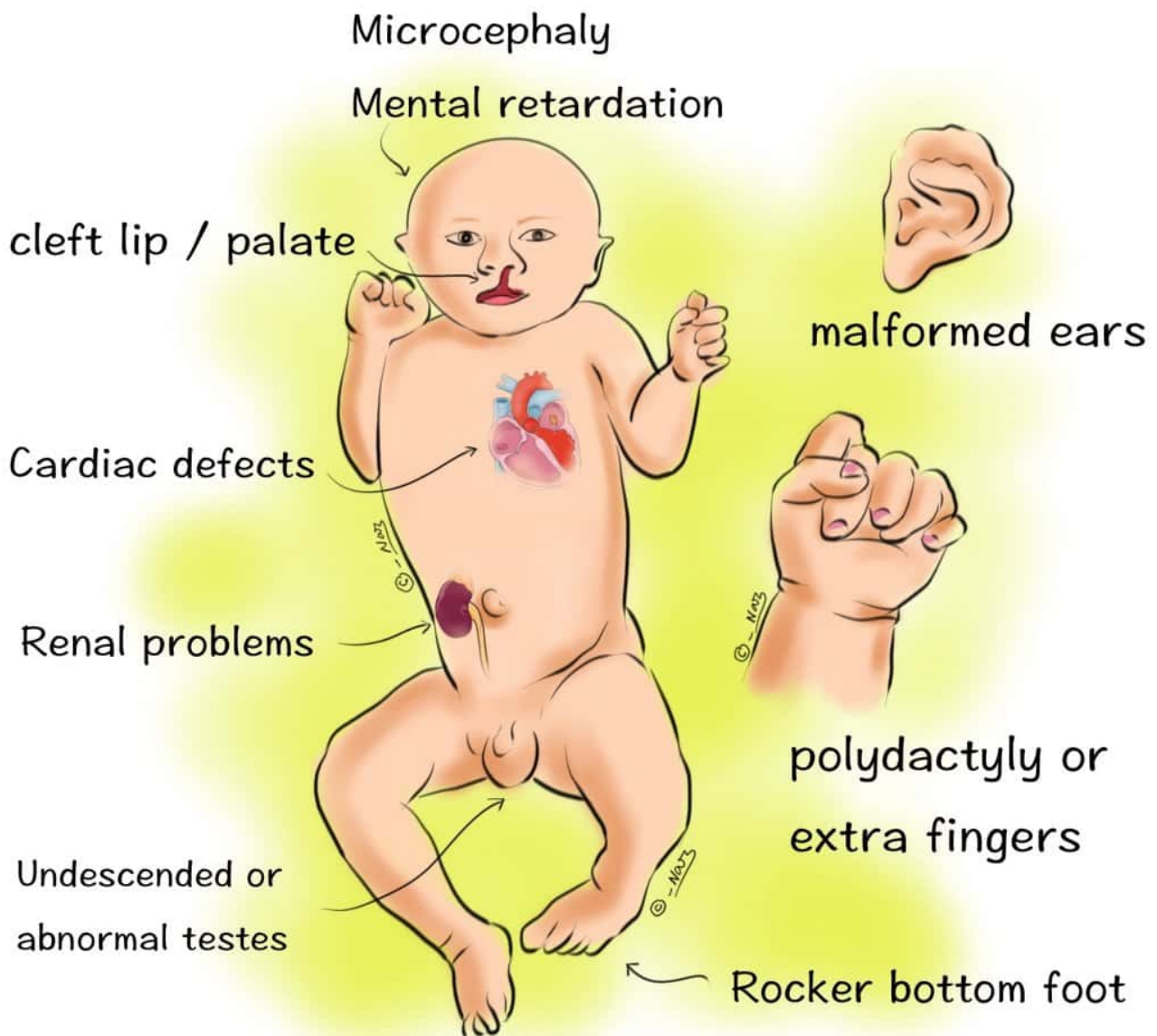
polydactyly or
extra fingers

Undescended or
abnormal testes

Rocker bottom foot

PATAU Syndrome

www.medinaz.com



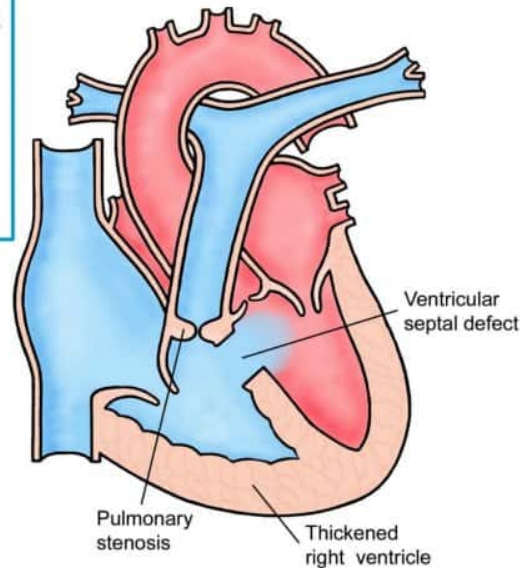
Right to Left Shunt

www.medinaz.com

Tetralogy of fallot
Tricuspid atresia
Truncus arteriosus
Transposition of
 great vessels

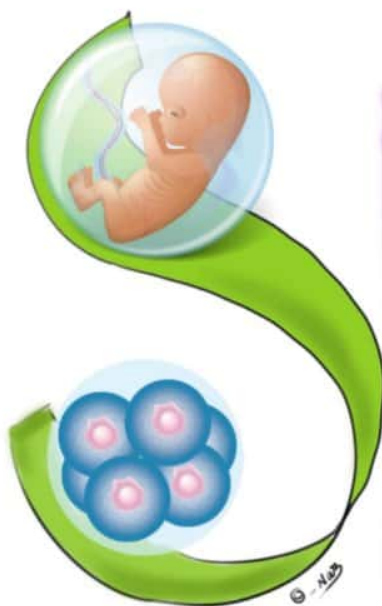
© - Naz

“4T”



Cartilage Derivatives of 2nd Branchial Arch

5 “S”



Steps
Styloid process
Stylohyoid ligament
Smaller(lesser) cornu of
 hyoid
Superior part of body
 of hyoid

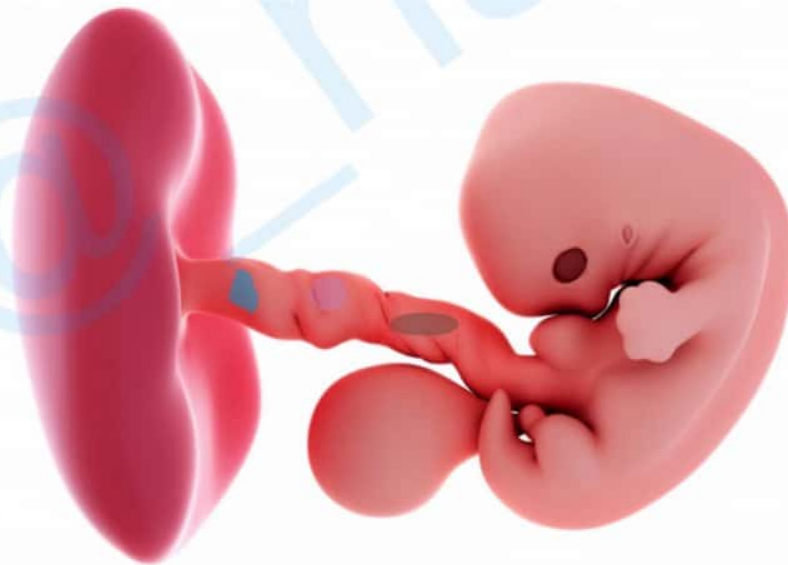
© - Naz

Teratogenesis

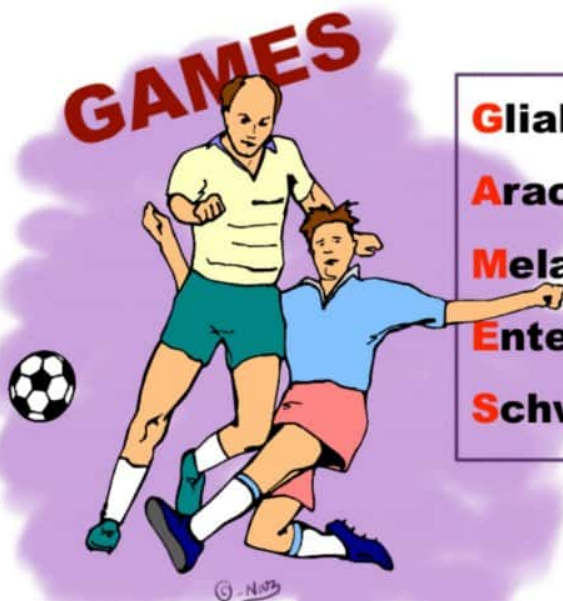TEratogenesis is most likely during organogenesis between the **T**hird and **E**ight weeks of gestation

© - NAB

www.medinaz.com



Cranial & Spinal Neural crest Major Derivatives



Glial cells(of peripheral ganglia)
Arachnoid & Pia
Melanocytes
Enteric ganglia
Schwann cells

© - NAB



HISTOLOGY

@NEETPGSURGEON



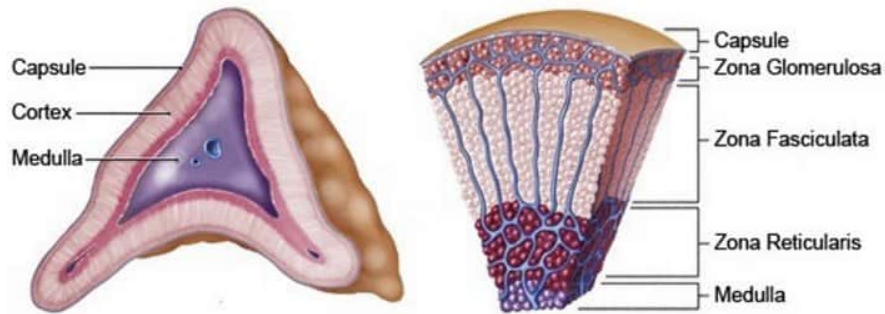
Adrenal Cortex Layers

www.medinaz.com

Glomerulosa
Fasciculata
Reticularis

“GFR”

© - Notz



Epiphyseal Plate : Zones



Rest People **H**ave
Career **O**pportunities

Resting zone
Proliferative zone
Hypertrophic zone
Calcified cartilage zone
Ossification zone

© - Notz

Collagen Fibres

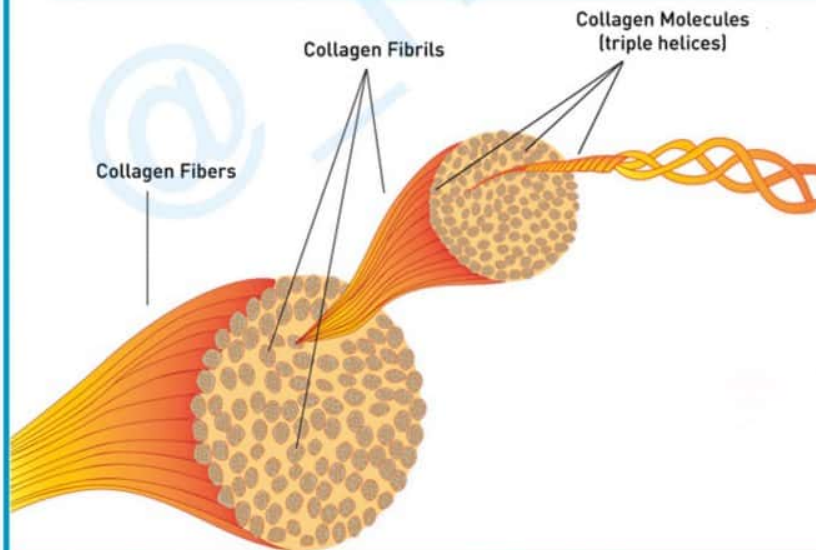
www.medinaz.com

Type **One** = **B**One

Type **Two** = **Car**Two**l**age (cartilage)

Type **Four** = **F**loor (basement membrane)

© - Nats



Collagen Fibres

www.medinaz.com

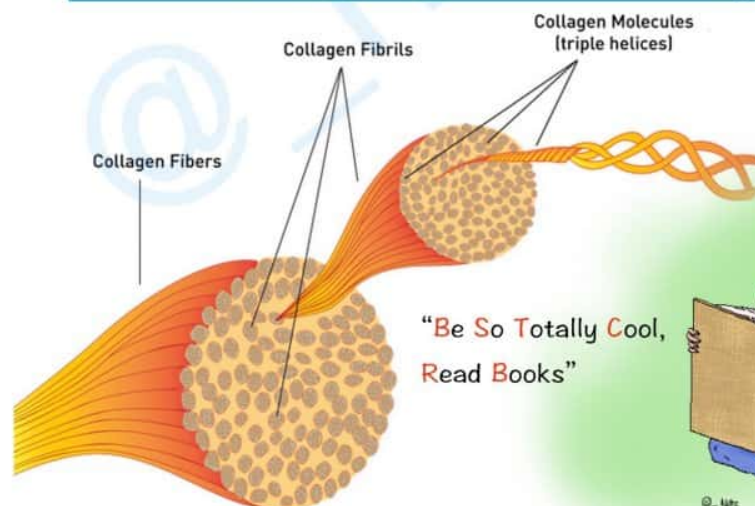
Type **1** = **B**one, **S**kin & **T**endon

Type **2** = **C**artilage

Type **3** = **R**eticulin & **B**lood vessels

Type **4** = **B**asement membrane

© - Nats



"Be So Totally **Cool**,
Read **B**ooks"

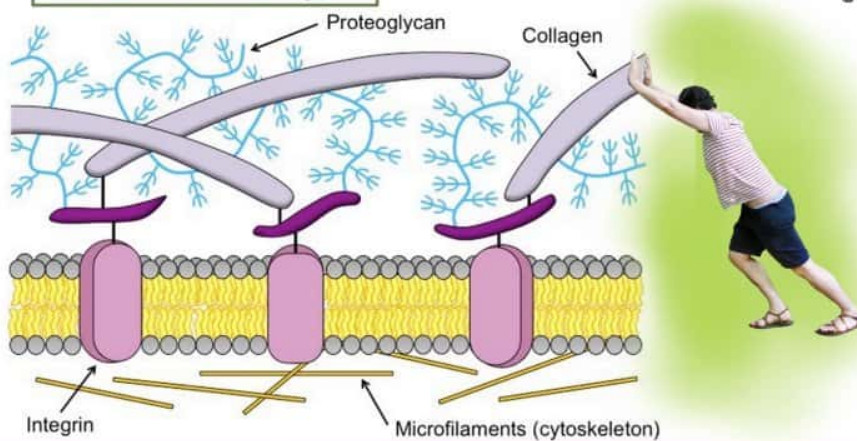


Extracellular Matrix Components

www.medinaz.com

Hyaluronic acid
Elastin
Laminin
Proteoglycan
Collagen
Fibronectin

“HELP Collagen Fibres”

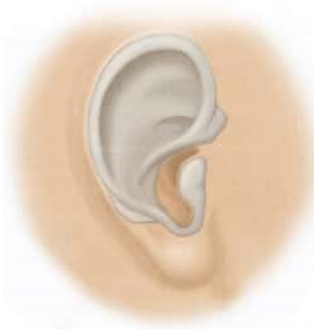
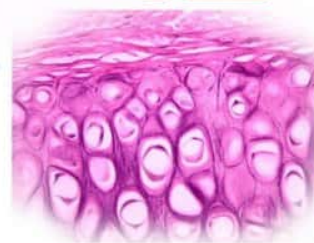
Elastic Cartilage present in

www.medinaz.com

Epiglottis
Ear pinna
External acoustic meatus
(lateral part)
Eustachian tube
(medial part)

4E



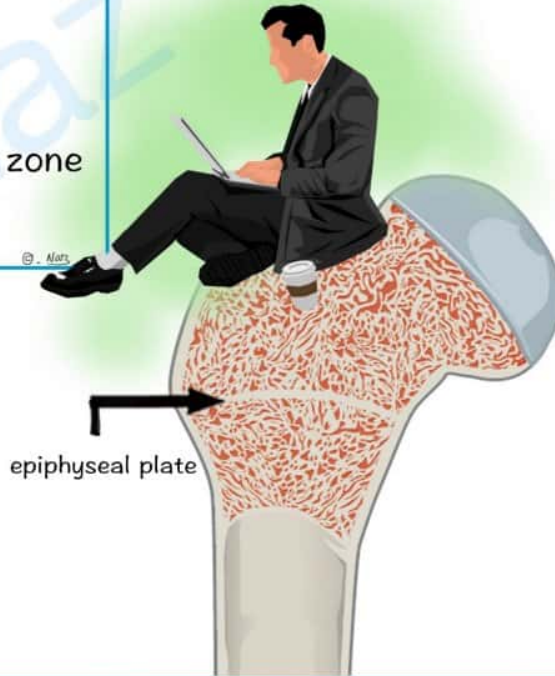


Epiphyseal Plate : Zones

www.medinaz.com

“Real People Have
Career Opportunities”

- Resting zone
- Proliferative zone
- Hypertrophic zone
- Calcified cartilage zone
- Ossification zone



Layers of Epidermis



C (SEE)

Lady Gaga's Sexy Back

STRATUM

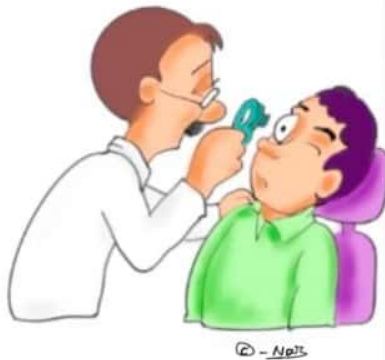- Corneum
- Lucidum
- Granulosum
- Spinosum
- Basale



naz_artonomy

Retinal Layers

www.medinaz.com



In → Int. Limiting membrane
New → Nerve fiber Layer
Generation → Ganglion cell Layer
It → Inner plexiform Layer
Is → I » Nuclear Layer
Only → Outer Plexiform »
Ophthalmologists → Outer nuclear Layer
Examining → Ex. Limiting membrane
Patient's → Photoreceptors
Retina → Retinal pigmented epithelium

© - No25



GROSS ANATOMY

ABDOMEN

@NEETPGSURGEON

ABDOMINAL MUSCLES

- T**ransversus abdominis
- I**nternal abdominal oblique
- R**ectus abdominis
- E**xternal abdominal oblique

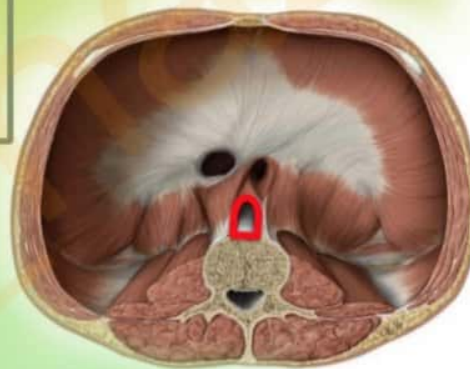“TY(i)RE”



Aortic Opening Contents

- A**ORTA
- T**horacic duct
- A**zygos vein

“AORTA”



Bowel Components

www.medinaz.com

proximal to distal..

Duodenum
Jejunum
Ileum
Appendix
Colon
Sigmoid
Rectum

“DJ Is A Cool
Singing Rockstar”

© - Med5



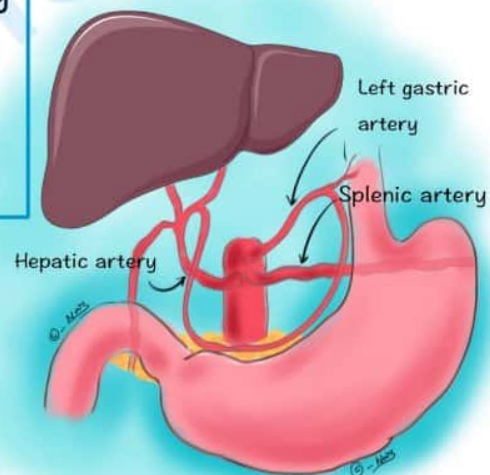
Celiac Trunk Branches

www.medinaz.com

“Left Hand Side”

Left gastric artery
Hepatic artery
Splenic artery

© - Med5





GROSS ANATOMY

HEAD & NECK

@NEETPGSURGEON

Axillary Artery Primary Branches

www.medinaz.com



Some → **S**uperior thoracic a.
Times → **T**horacoacromial a.
Life → **L**ateral thoracic a.
Seems → **S**ubscapular a.
A → **A**nt. Circumflex humeral a.
Pain → **P**ost. Circumflex humeral a.

Bell's Palsy Symptoms

“**BELL'S P**alsy”

Blink reflex abnormal
Earache
Lacrimation
Loss of taste
Sudden onset
Palsy of 7th
nerve muscles

All symptoms are **Unilateral**





Carotid Sheath Contents

www.medinaz.com

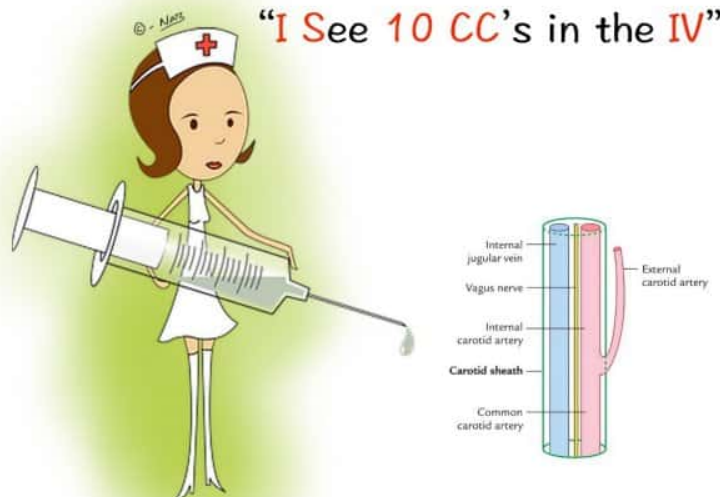
I see (**I.C.**) = **I**nternal **C**arotid artery

10 = **CN 10** (Vagus nerve)

CC = **C**ommon **C**arotid artery

IV = **I**nternal **J**ugular **V**ein

© - Matt



Cranial Bones

www.medinaz.com

Sphenoid

Temporal

Ethmoid

Parietal

Occipital

Frontal

© - Matt

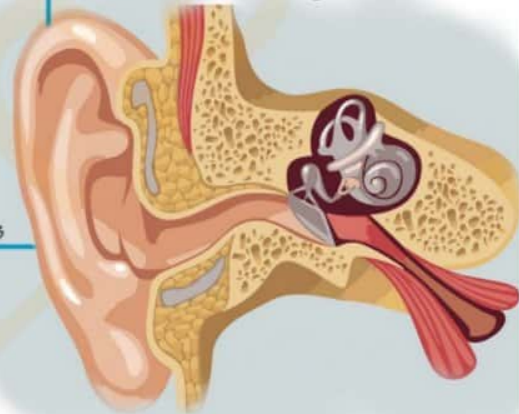
"STEP OFF" my skull



Elastic Cartilage Present

“ACE”

Auricle & **A**uditory tube
Cuneiform cartilage
Epiglottis & **E**xternal
auditory canal



Eye Rotation by Oblique Muscles

www.medinaz.com

SMILE

eye rotation

Superior Oblique =
Medial eye rotation

Inferior Oblique =
Lateral eye rotation




Facial Bones

www.medinaz.com

Vomer
 Conchae
 Nasal
 Maxilla
 Mandible
 Palatine
 Zygomatic
 Lacrimal

“Viagra Can Not Make
 Man’s Penis Zebra Like”



Nasal Septum - Osseous part

Vomer
 Sphenoid
 Nasal bone
 Frontal bone
 Ethmoid
 Palatine
 Maxillary

Very
 Special
 News
 For
 Egyptian
 PM

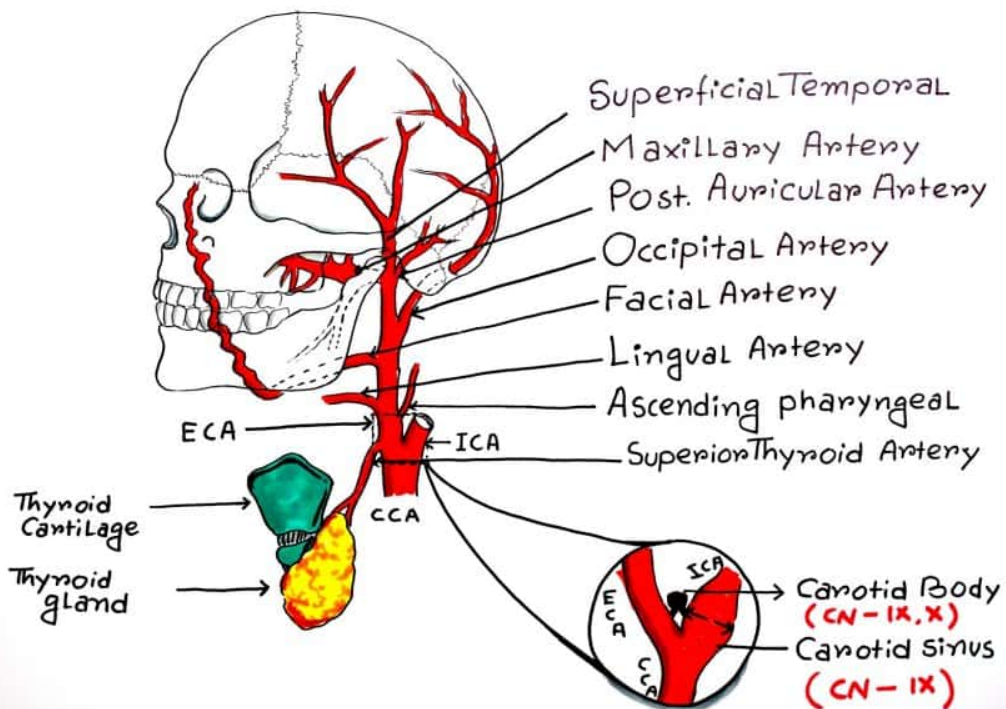


External carotid artery branches

ECA

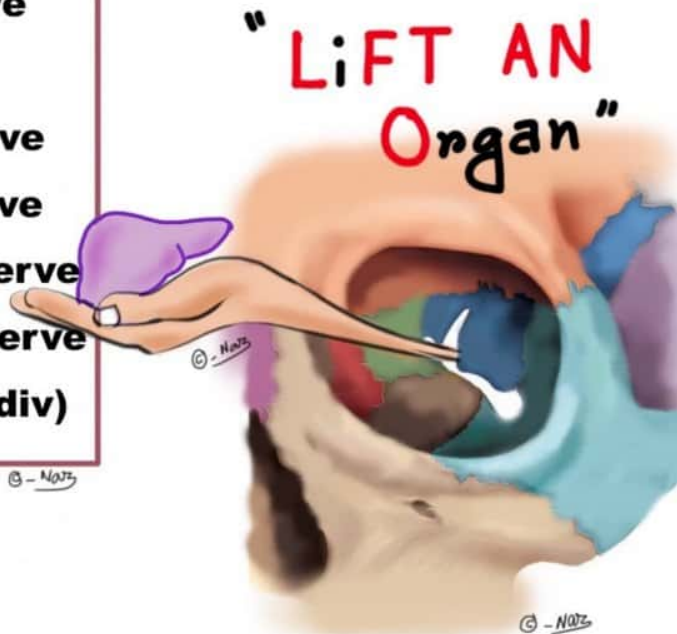


- S**ome → **S**uperior thyroid
- A**ngry → **A**scending Pharyngeal
- L**ady → **L**ingual
- F**igured → **F**acial
- O**ut → **O**ccipital
- P**ost → **P**osterior auricular
- M**enopausal → **M**axillary
- S**yndrome → **S**uperficial Temporal



Nerves Passing Through Superior Orbital Fissure

Lacrimal nerve
Frontal nerve
Trochlear nerve
Abducent nerve
Nasociliary nerve
Oculomotor nerve
 (sup. and inf. div)



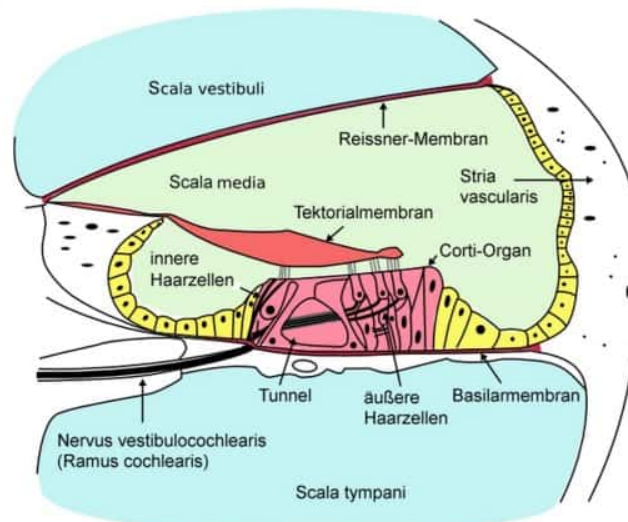
Corti Organ Location

www.medinaz.com

COrti present inside the
COchlea

© - Natz

© - Natz



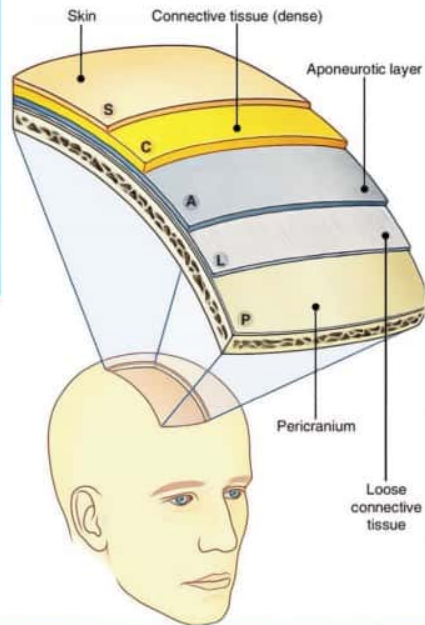
Scalp Layers

www.medinaz.com

- S**kin
- C**onnective tissue (dense)
- A**poneurotic layer
- L**oose connective tissue
- P**ericranium

© - Natz

“SCALP”



Extrinsic Muscles of Tongue

www.medinaz.com

- H**yglossus
- S**tyloglossus
- G**enioglossus
- P**alatoglossus

© - Natz

“Highly **S**tylesh & **G**enius Princess”

© - Natz





Subclavian Artery Branches

www.medinaz.com

Very	→	V ertebral artery
Interesting	→	I nternal thoracic art.
Thing,	→	T hyrocervical trunk
I	→	I nferior thyroid art.
Served	→	S uprascapular art.
The	→	T ransverse cervical art.
Country	→	C ostocervical art.
Since	→	S uperior intercostal art.
Dat(that)	→	D eep cervical art.
Day	→	D orsal scapular art.

© - NMS

**Very Interesting Thing, I Served
The Country Since Dat(that) Day**

© - NMS





Subclavian Artery Main Branches

www.medinaz.com



“**VIT**amin **C** & **D**”

Vertebral artery

Internal thoracic

Thyrocervical trunk

Costocervical trunk

Dorsal scapular



INFERIOR VENA CAVA **TRIBUTARIES**



I → **I**liac vein (c)

Like → **L**umbar veins

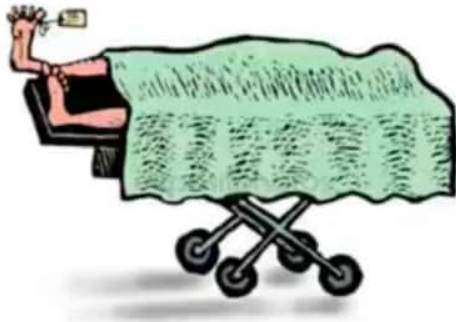
To → **T**esticular veins

Rise → **R**enal veins

So → **S**uprarenal veins

High → **H**epatic veins

Thoracoacromial artery branches Mnemonic




Cadavers → **C**lavicular br.

Are → **A**cromial br.

Dead → **D**eltoid br.

People → **P**ectoral br.

Sub scapular artery branches Mnemonic



STd

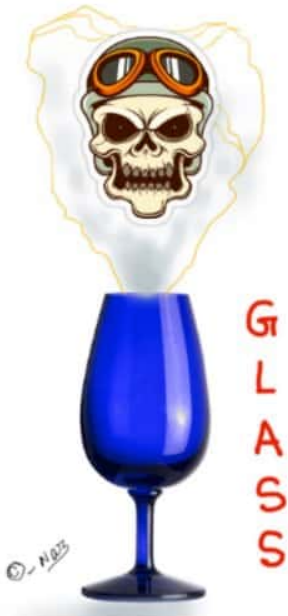↓

Scapular
Circumflex

↓

Thoraco
Dorsal

SCALP NERVE SUPPLY



Greater Occipital / **G**reat auricular
Lesser Occipital
Auriculotemporal
Supratrochlear
Supraorbital

© - 1975



GROSS ANATOMY

UPPER LIMB

@NEETPGSURGEON

Brachial Plexus: branches of posterior cord

www.medinaz.com

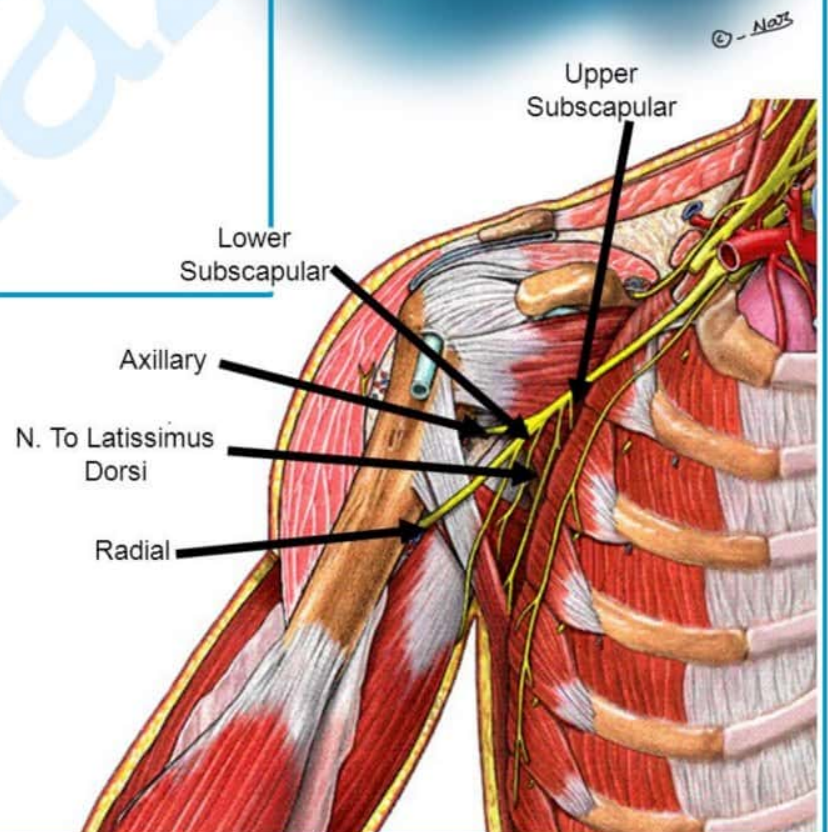
“STAR”

Subscapular (upper & lower)

Thoracodorsal

Axillary

Radial





Brachial Plexus Subunits

www.medinaz.com

Roots
Trunks
Divisions
Cords
Branches

© - Naitz

“**R**egular **T**een **D**rinks
Cold **B**eer”



Brachial Plexus Branches

www.medinaz.com

from lateral to medial:

Musculocutaneous
Axillary
Radial
Median
Ulnar

© - Naitz

“**M**y **A**RM **U**p”



www.medinaz.com

Carpal Bones

Scapoid
Lunate
Triquetrum
Pisiform
Trapezium
Trapezoid
Capitate
Hamate

She **L**ooks **T**oo **P**retty
Try **T**o **C**atch **H**er

© - NAB



© - NAB

Clavipectoral Fascia

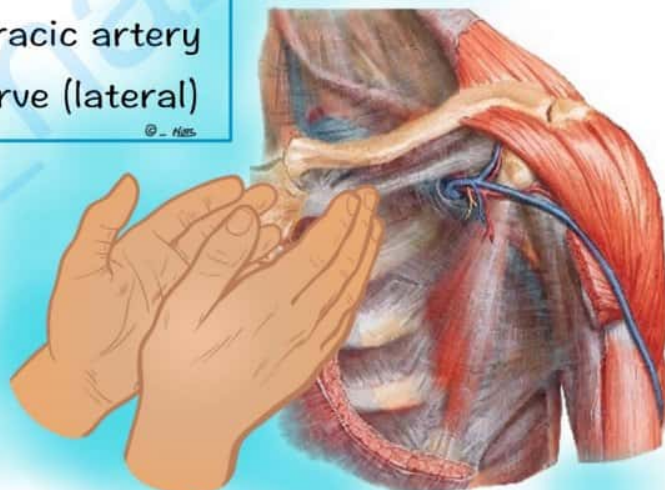
www.medinaz.com

Cephalic vein
Lymphatic vessels
Acmiothoracic artery
Pectoral nerve (lateral)

© - NAB

“**CLAP**”

© - NAB



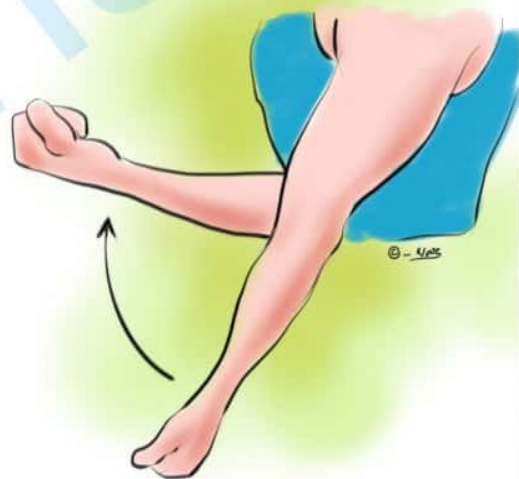
Elbow Flexion Muscles

www.medinaz.com

Biceps
Brachialis
Brachioradialis

© - Med

“3 B’s Bend the elbow”



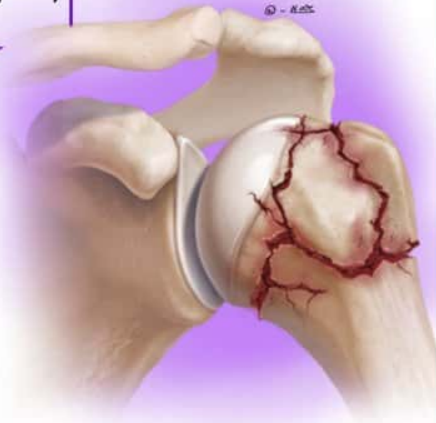Nerves Injured in Humerus Fracture

www.medinaz.com

Axillary nerve (Head)
Radial nerve (Mid shaft)
Median nerve (Supracondylar)

© - Med

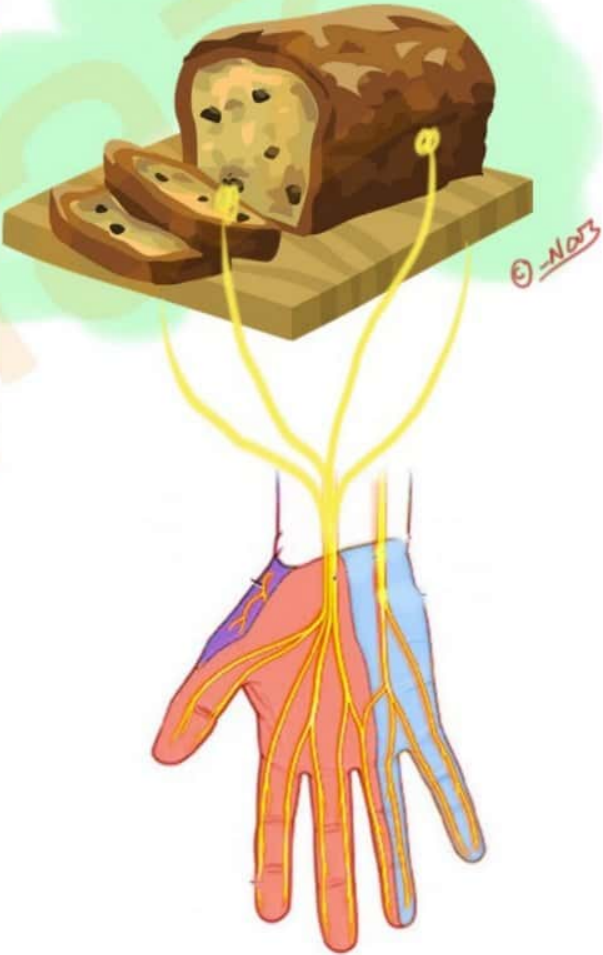
“**ARM**”



Muscles supplied by Median nerve

“LOAF”

- L**ateral two lumbricals
- O**pponens pollicis
- A**bductor pollicis brevis
- F**lexor pollicis brevis





GROSS ANATOMY

LOWER LIMB

@NEETPGSURGEON

Tarsal Bones

Talus

Calcaneus

Navicular

Medial cuneiform

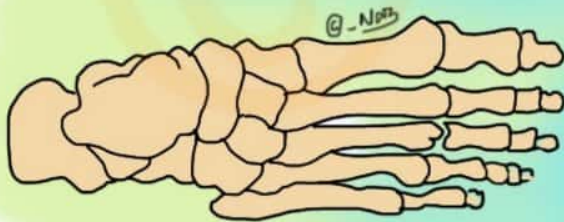Intermediate cuneiform

Lateral cuneiform

Cuboid

© - No73

The **C**ircus Needs More
Interesting **L**ittle **C**lowns



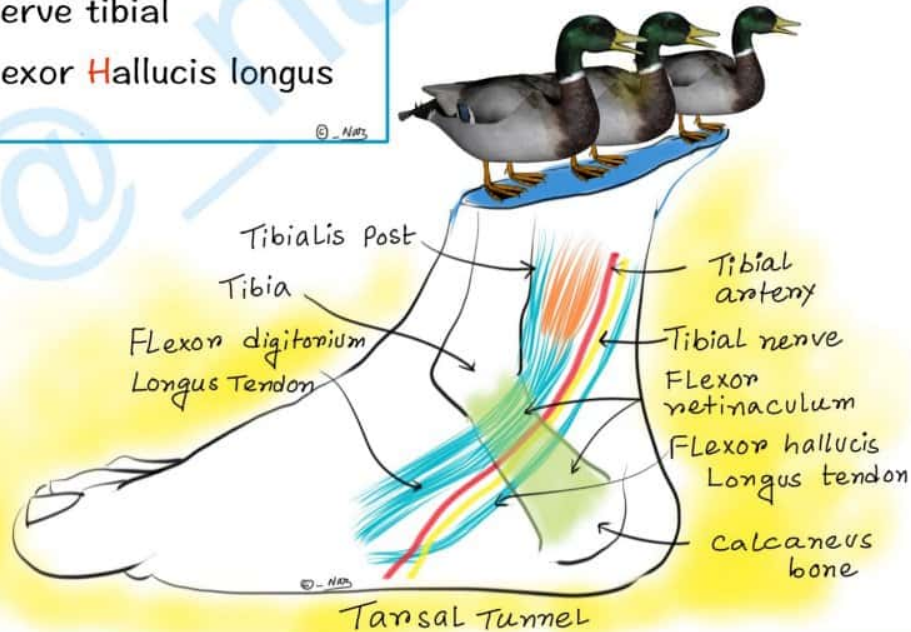
© - No73

Tarsal Tunnel Contents

www.medinaz.com

Tibialis posterior
 flexor Digitorum longus
 Artery posterior tibial
 Nerve tibial
 flexor Hallucis longus

“These Ducks Are
 Not Hungry”



Tibia Muscle Attachments

www.medinaz.com

“Please Engage with The
 Tall Slim Girl”

Peroneus longus
 Extensor digitorum longus
 Tibialis anterior
 Tibialis posterior
 Soleus
 Gastrocnemius





GROSS ANATOMY

THORAX

@NEETPGSURGEON



Deep Muscles of Back

www.medinaz.com

Splenius capitis
Erector spinae
Interspinales
Intertransversarii
Splenius cervicis
Transversospinalis
Semispinalis
Multifidus
Rotatores

“Senior Engineer Invited
In States To See
Machines Running”

© - Naz



© - Naz

www.medinaz.com



Nerve root supply of long thoracic nerve which innervates serratus anterior

www.medinaz.com

C5, C6, C7

“Five(5) six(6), seven (7) raise
your arms to heaven”



Vertebral Level Openings

www.medinaz.com

Venacava

8 letters = **T8**

© - NMS

Oesophagus

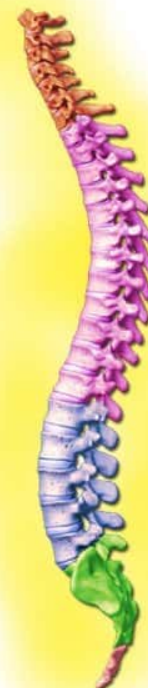10 letters = **T10**

© - NMS

Aortic Hiatus

12 letters = **T12**

© - NMS



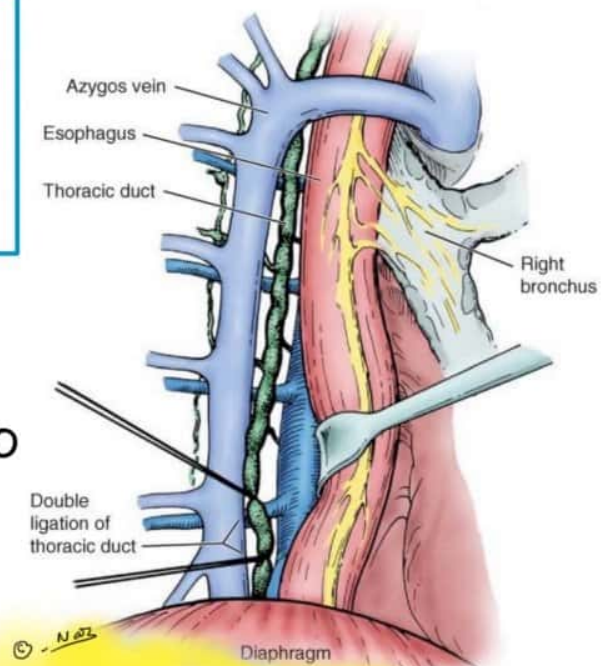
Relationship of Thoracic Duct

www.medinaz.com


Duck = Thoracic **Duct**

2 **Gooses** = esopha**Gus** & azy**Gos** vein

© - Naz



“The **Duck** is between two **Gooses**”





GROSS ANATOMY

PELVIS

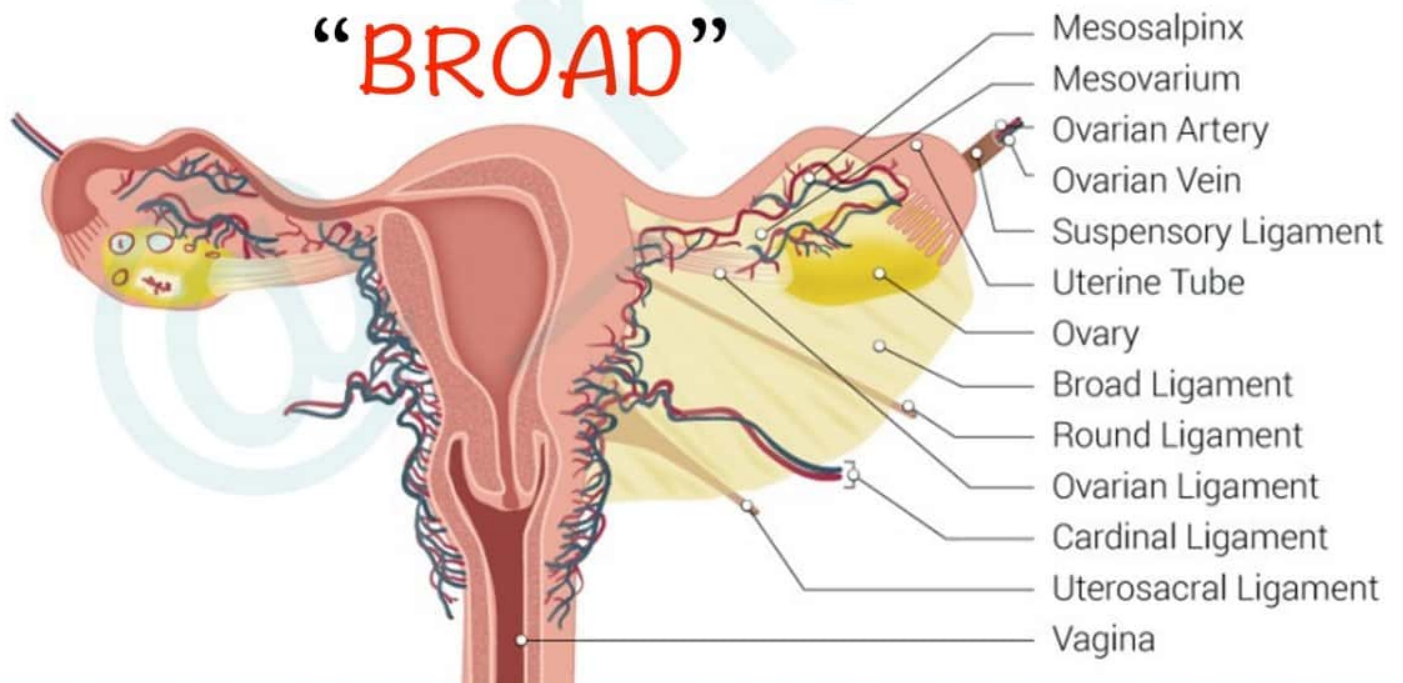
@NEETPGSURGEON

Broad Ligament Contents

www.medinaz.com

- Bundle (ovarian neurovascular bundle)
- Round ligament
- Ovarian ligament
- Artefacts (vestigial structures)
- Duct (oviduct)

© - NAZ

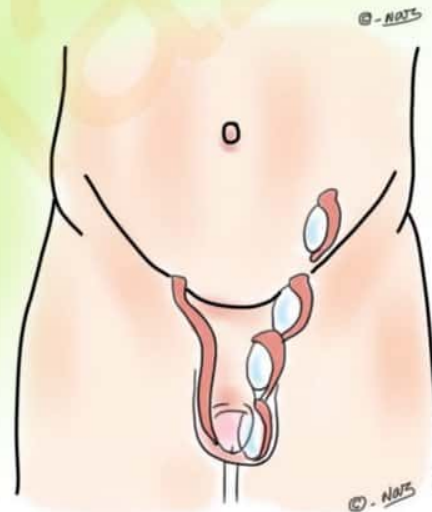




Complications of Undescended Testis (Cryptorchidism)

- Tumor**
- Epididymo orchitis**
- Seminoma**
- Torsion, Trauma**
- Inguinal Hernia**
- Sterility**

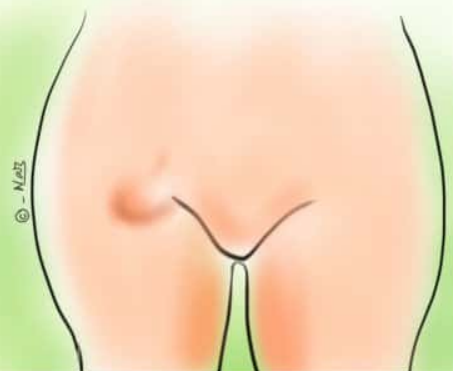“ **TESTIS** ”



Femoral Hernia

www.medinaz.com

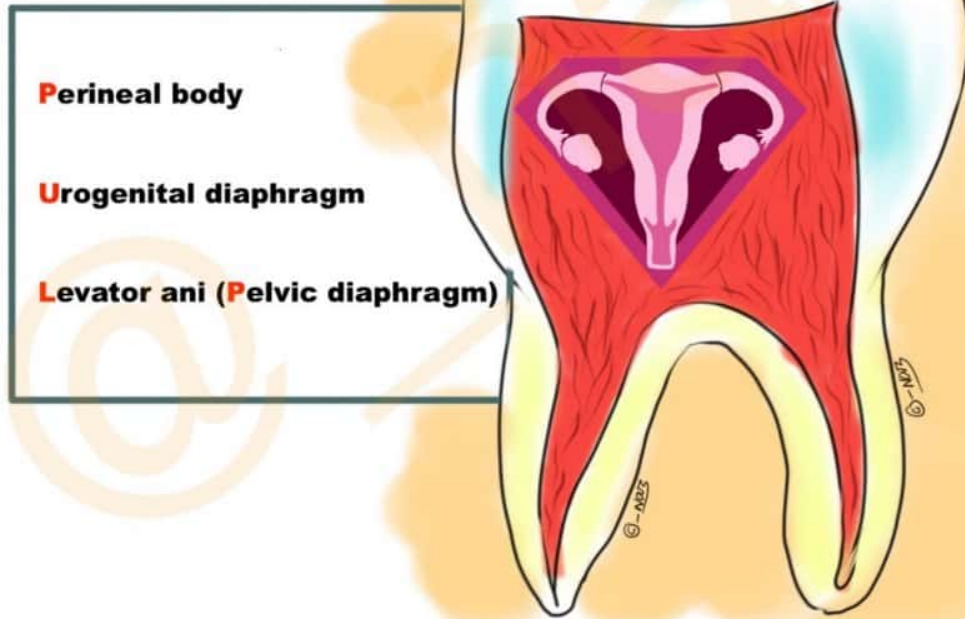
FEMoral Hernia most commonly occurs in **FEM**ale



www.medinaz.com

Muscular support of Uterus

“PULP”

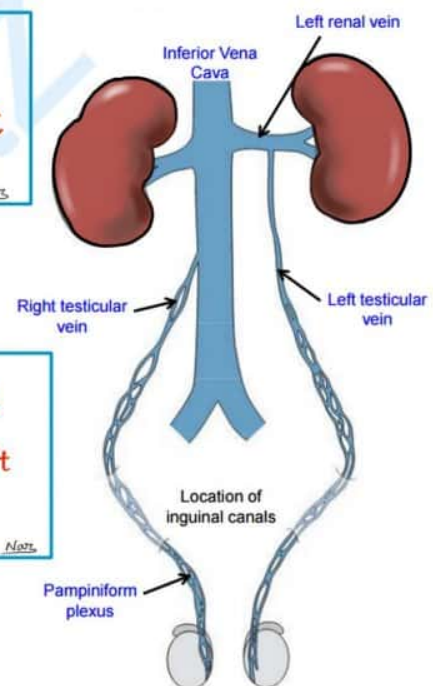


Testicular Vein Drainage

www.medinaz.com

Right Testicular vein
Rightly drained to the **IVC**

Left Testicular vein was **Left**
out and hence drained to **Left**
Renal vein





MISCELLANEOUS

@NEETPGSURGEON

DiGeorge syndrome



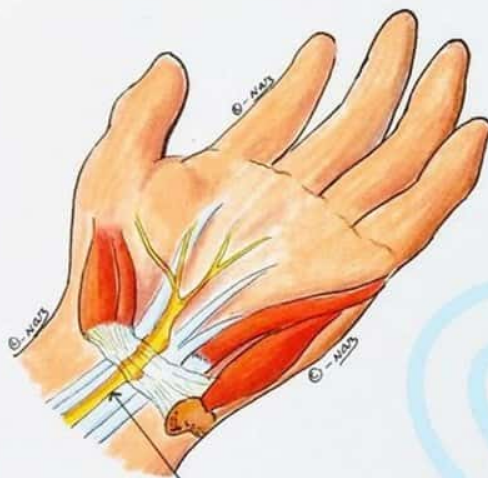
22



Cardiac abnormalities
Abnormal Facies
Thymic Aplasia
Cleft Palate
Hypocalcemia
22q11 deletion

Carpal tunnel syndrome

(causes)

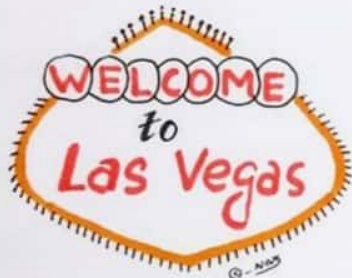


Compressed
Median nerve

Myxoeidema
Edema Pre-menstrually
Diabetes
Idiopathic
Acnomegaly
Neoplasm
Trauma
Rheumatoid arthritis
Amyloidosis
Pregnancy

Cardiac tissue conduction velocity

Mnemonic:
Party At
Vegas Avenue



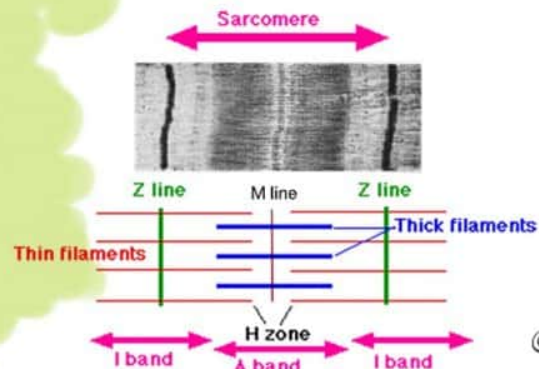Purkinje System
↓
Atrial muscle
↓
Ventricular muscle
↓
Av node



SARCOMERE STRUCTURE

Zahir Is A Hungry Man

Z line I band A band H zone M line



© - NIOS

Auscultation Triangle

www.medinaz.com

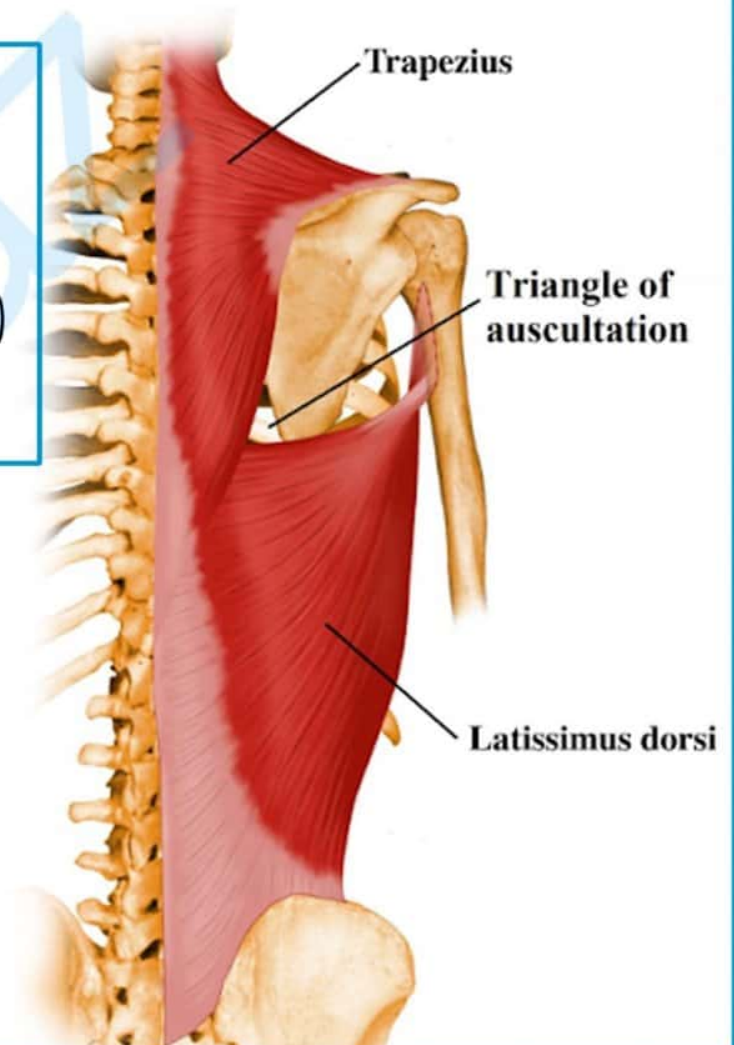
“auSCuLTation”

SCapula (laterally)

Lattismus dorsi (inferiorly)

Trapezius (sup. & medially)

© - NRS



Autosomal Dominant Disorders

Mnemonic → **“Very Powerful DOMINANT Human”**

Von willebrand disease / **V**on hippel-lindau

Pseudo-hypoparathyroidism

Dystrophia myotonica

Osteogenesis imperfectif / **O**sler-weber-rendu

Marfan syndrome

Intermittent porphyria

Neurofibromatosis

Achondroplasia / **A**dult polycystic kidney dis.

Noonan syndrome

Tuberous sclerosis

Hypercholesterolemia

Huntington’s disease

Hypertrophic obstructive cardiomyopathy

Hereditary spherocytosis

Hereditary non polyposis coli

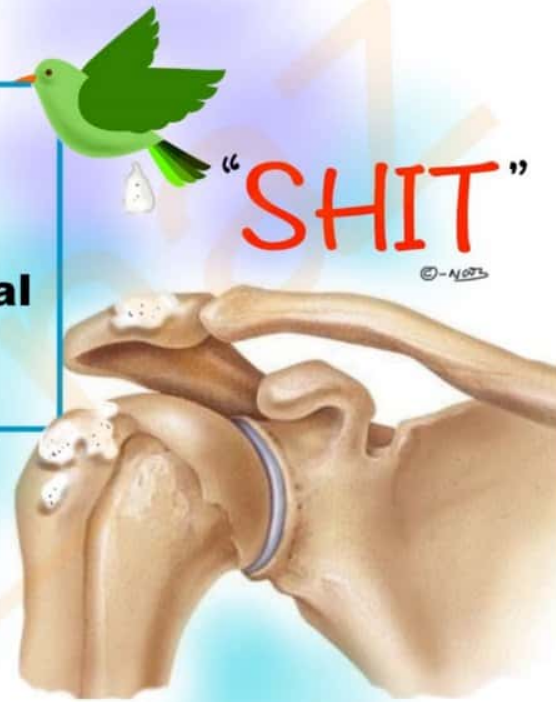Hereditary hemorrhagic telangiectasia





Ball & Socket Joints

- S**houlder
- H**ip
- I**ncudostapedial
- T**alonavicular



CELL CYCLE STAGES



- Go** → **G1** phase
- Simran** → **S** phase
- Go** → **G2** phase
- Make** → **M** phase
- Chicken** → **C** phase



EDWARDS SYNDROME

Eighteen (trisomy)

Digit overlapping flexion

Wide head

Absent intellect (mentally retarded)

Rocker bottom feet

Diseased heart

Small lower jaw (Mircrognathia)

© - NQ3

